American Journal of Ophthalmology Case Reports 27 (2022) 101673

Contents lists available at ScienceDirect

American Journal of Ophthalmology Case Reports

journal homepage: www.ajocasereports.com/

Panuveitis induced by donor-derived CD8$^+$ T cells after allogeneic hematopoietic stem cell transplantation for adult T-cell leukemia

Atsunobu Takeda [a,*], Teppei Sakoda [b], Nobuyo Yawata [a,c], Koji Kato [b], Eiichi Hasegawa [a], Takahiro Shima [b], Shinichi Hikita [a], Keiko Yoshitomi [a], Katsuto Takenaka [d], Yoshinao Oda [e], Koichi Akashi [b], Koh-Hei Sonoda [a,c]

[a] Department of Ophthalmology, Japan
[b] Department of Medicine and Biosystemic Science, Japan
[c] Department of Ocular Pathology and Imaging Science, Japan
[d] Department of Hematology, Clinical Immunology, and Infectious Diseases, Graduate School of Medicine, Ehime University, Japan
[e] Department of Anatomic Pathology, Graduate School of Medical Sciences, Kyushu University, Fukuoka, Japan

ARTICLE INFO

Keywords:
Adult T cell leukemia
Allogeneic hematopoietic stem cell transplantation
Human T-cell lymphotropic virus type-1
Donor-derived CD8$^+$ T lymphocytes
HTLV-1-Associated uveitis

ABSTRACT

Purpose: This article presents a case of panuveitis that occurred after unrelated allogeneic hematopoietic stem cell transplantation (allo-HSCT) in a patient with lymphoma-type human T-cell leukemia virus type-1 (HTLV-1)-associated adult T-cell leukemia (ATL).

Observations: A 45-year-old man developed unilateral panuveitis 18 months after undergoing allo-HSCT. He underwent vitrectomy, and depositions of grey-white granules localized on the retinal artery were observed in the eye. Cytological examination of the vitreous aspirates showed that the atypical lymphoid cells stained positive for CD3 and CD8, but negative for CD4, B-cell markers, and cytomegalovirus antigen. Interphase fluorescence in situ hybridization using X- and Y-chromosome probes revealed complete donor chimerism in CD8$^+$ T cells in the vitreous aspirates.

Conclusions and importance: Donor-derived CD8$^+$ T lymphocytes can induce panuveitis like HTLV-1-assiciated uveitis after allo-HSCT in patients with ATL. Pathological diagnosis of vitreous infiltration by vitrectomy is helpful in patients with ATL. Donor-derived CD8$^+$ T lymphocytes-induced panuveitis is recurrent but susceptible to regional corticosteroid treatment.

1. Introduction

Adult T-cell leukemia (ATL) is a rare lymphoproliferative malignancy caused by chronic infection of the human T-cell leukemia virus type-1 (HTLV-1).[1] The annual rate of ATL is estimated to between 7.7 and 8.7 per 10,000 in HTLV-1 carriers.[2] The 4-year overall survival is 24.8% with the mean survival time of 11.7 months in patients with ATL in a recent nationwide hospital-based study in Japan.[3] ATL is divided into four clinical subtypes, including acute, lymphoma, chronic, and smoldering. Among them, acute, lymphoma, and chronic types with unfavorable prognostic factors types are categorized as aggressive ATL and were associated with a poor prognosis; the median survival time was 8–10 months.[4] Thus, because of the rarity and poor prognosis of ATL, there have been limitations to note ocular manifestations in ATL. Recently, a survey of cases of ocular manifestation of ATL have revealed that intraocular infiltration of ATL is the most prevalent in Japan, followed by opportunistic infections, such as those of cytomegalovirus (CMV), herpesvirus, and *Toxoplasma gondii*.[5] Inflammatory cell infiltration, the clinical features of which resemble HTLV-1-associated uveitis (HAU), was also described as a consequence of ATL invasion.[6,7] Therefore, it is necessary to determine the phenotypes of cells infiltrating the eye of ATL patients because treatment plans differ for ATL cell invasion, opportunistic infections, and inflammatory cell infiltrates such as HAU.

HTLV-1 virus remain latent for a long time by maintaining a low rate of replication, which can induce inflammation in the central nervous system (CNS) and eye, cause genetic changes, or augment cell growth.[8] HAU and HTLV-1-associated myelopathy/tropical spastic paraparesis

* Corresponding author. Department of Ophthalmology, Graduate School of Medical Sciences, Kyushu University, 3-1-1 Maidashi, Higashi-Ku, Fukuoka, 812-8582, Japan.

E-mail address: takeda.atsunobu.248@m.kyushu-u.ac.jp (A. Takeda).

https://doi.org/10.1016/j.ajoc.2022.101673
Received 12 May 2022; Received in revised form 11 July 2022; Accepted 22 July 2022
Available online 5 August 2022
2451-9936/© 2022 The Authors. Published by Elsevier Inc. This is an open access article under the CC BY-NC-ND license (http://creativecommons.org/licenses/by-nc-nd/4.0/).

(HAM/TSP) are chronic inflammatory disorders caused by HTLV-1 infection in the CNS and eye.[9] Although HTLV-1 infection causes ATL, HAU, and HAM/TSP, the strength of HTLV-1-specific cytotoxic T-cell (CTL) responses, which serve as anti-tumor or anti-virus immunity, is different among ATL, HAU and HAM/TSP patients.[10] HTLV-1-specific $CD8^+$ CTLs are reportedly active for long-term in patients with HAM/TSP,[11] suggesting that HAU is evoked by a HTLV-1-specific monoclonal population of cells. On the other hand, although ATL has a poor prognosis since early after its onset, ATL progresses slowly as it takes decades for HTLV-1-infected T cells to transform into ATL cells via genetic changes and deficiency or anergy of HTLV-1-specific CTL responses.[8,10] Allogeneic HSCT restores HTLV-1-specific CTL responses in patients with ATL who have survived without any relapse in a long time after HSCT.[12]

To our knowledge, this is a primary report of panuveitis in a patient who had infiltration of donor-derived CD8-positive cells after allogeneic hematopoietic stem cell transplantation (allo-HSCT) for aggressive ATL, although the principal phenotype of ATL or inflammatory cells in HAU is $CD4^+$ cells.[9]

2. Case report

A 45-year-old man was diagnosed with lymphoma-type HTLV-1-associated ATL. Unrelated allo-HSCT from a HTLV-1-negative donor, after a conditioning regimen with 12 Gy of total irradiation, 120 mg/kg cyclophosphamide, and 12 g/m^2 cytarabine, was done at the Department of Hematology, Kyushu University Hospital. Subsequently, 5 mg of prednisolone and 2 mg of tacrolimus were systemically administered to prevent rejection of transplanted cells after allo-HSCT. Twelve months after allogeneic HSCT, since ATL recurred as a skin rash on the right thigh, he underwent chemotherapy. According to the response criteria proposed by Japan Clinical Oncology Group,[13] we assessed complete response (CR) based on the following findings: no abnormal accumulation in fluorodeoxyglucose-positron emission tomography/computed tomography, and absence of skin disease and abnormal lymphocytes in bone marrow and peripheral blood. However, 18 months after allo-HSCT, the patient complained of sudden blurred vision in the right eye and was referred to the eye clinic at the Department of Ophthalmology, Kyushu University Hospital. He had no history of ocular diseases. His best-corrected visual acuity (BCVA) was 20/32 oculus dexter (OD) and 20/20 oculus sinister (OS) at the initial examination. The intraocular pressure was 26 mmHg OD and 12 mmHg OS. A moderate anterior chamber reaction (2^+ cells) with flare, mutton-fat keratic precipitates, anterior synechiae, and mild vitreous inflammation were observed in the right eye on slit lamp examination. Diffuse mild vitreous opacity was observed in the right eye on fundus examination (Fig. 1a). Ultrasonographic examination revealed granular vitreous opacities (Fig. 1b). Optical coherence tomography findings for the macula were normal (Fig. 1c). The patient's left eye exhibited no evidence of inflammation. Increased levels of serum lactate dehydrogenase or soluble IL-2 receptor, which generally indicates ATL disease progression, were not observed in blood test. In addition, white blood cells segmentation and counting demonstrated that there was no propagation of abnormal lymphocytes in peripheral blood. Based on these findings, we ruled out systemic recurrence of ATL. Furthermore, we disregarded the possibilities of autoimmune disease and infectious disease as there was no elevation in the anti-nuclear antibody titer and serum C-reactive protein levels. Brain imaging findings were unremarkable. Cerebrospinal fluid examination showed 8 white blood cells per microliter but no atypical lymphoid cells. In the aqueous humor, the HTLV-1 proviral load was positive on real-time polymerase chain reaction (PCR) analysis, and the cellular specimen was not represented by any malignant lymphoid cells.

The patient was started on topical 0.1% betamethasone eye drops 4 times per day; and dorzolamide hydrochloride and timolol maleate twice per day. However, the vitreous opacity worsened, and BCVA decreased to 20/100. Two weeks after the initial visit, he underwent a diagnostic vitrectomy of the right eye. The results of multiplex and broad-range PCR of the vitreous sample were positive for HTLV-1 proviral DNA, but negative for other viruses [herpes simplex virus (HSV) type-1, HSV-2, varicella zoster virus, cytomegalovirus, Epstein-Barr virus (EBV)], parasitic (toxoplasma), bacterial, and fungal infections. A cellular specimen from the vitreous was comprised of $CD8^+$ T-cells but no malignant lymphoid cells. Immunohistochemistry showed that the atypical lymphoid cells stained positive for CD3 and CD8 (Fig. 2a) but negative for CD4, B-cell marker (CD20 and CD79A), and CMV antigen. In situ hybridization did not reveal EBV-encoded small RNAs. Interphase fluorescence in situ hybridization using X- and Y-chromosome probes revealed that complete donor chimerism in 200/200 of $CD8^+$ cells in vitreous aspirates (Fig. 2b). Fundus examination showed depositions of grey-white granules localized on the retinal artery in the eye (Fig. 2c), which resembled a clinical feature of HAU. Fluorescein angiography demonstrated hyperfluorescence around the macula, granular hypofluorescence spots on the retinal artery, and no leakage from the vessels (Fig. 2d). The hypofluorescence spots were consistent with the location of grey-white granules (Fig. 2e).

The patient was diagnosed with panuveitis similar to HAU because the clinical features resembled those of HAU.[14] After treatment with sub-Tenon's triamcinolone acetonide injection (STTA) in combination with topical 0.1% betamethasone eye drops 4 times per day, ocular inflammation suppressed and depositions of grey-white granules gradually disappeared from the retinal artery. Therefore, the eye drops were discontinued 3 months later. Uveitis recurrence was observed in the anterior chamber and vitreous cavity 2 years after vitrectomy, and the patient responded well to STTA. Intraocular inflammation in the right eye had been inactive for 4 years since the recurrence. His BCVA was maintained 20/20 OD at his final visit.

3. Discussion

It is crucial to determine ATL cell invasion of the CNS, including the eye, because CNS progression has been observed 10–20% of patients with aggressive ATL with fatal outcomes in a short period.[15] In the present case, analysis of vitreous samples revealed that the infiltrated vitreous cells obtained were donor-derived $CD3^+$, $CD4^-$, and $CD8^+$ T lymphocytes but not $CD4^+$ T lymphocytes. Although HTLV-1 virus can

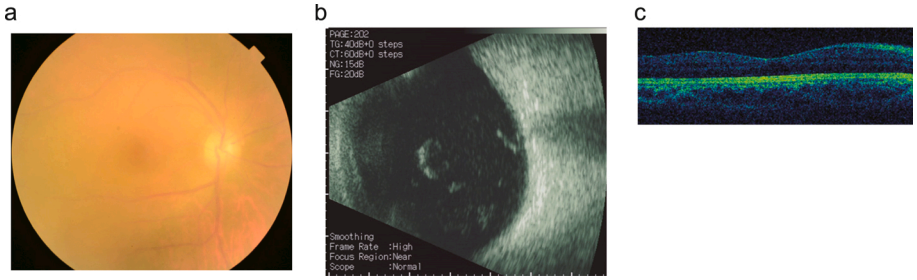

Fig. 1. A 45-year-old man with adult T-cell leukemia presented panuveitis and vitreous humor infiltration with the donor-derived CD8-positive cells after allogeneic hematopoietic stem cell transplantation. (**a**) Fundus photograph of the right eye showing diffuse mild vitreous haziness with granular opacities. (**b**) B-mode ultrasonography image showing granular vitreous opacities, although granular opacities are not clearly visible. (c) Optical coherence tomography of the macula in the right eye showing a normal appearance.

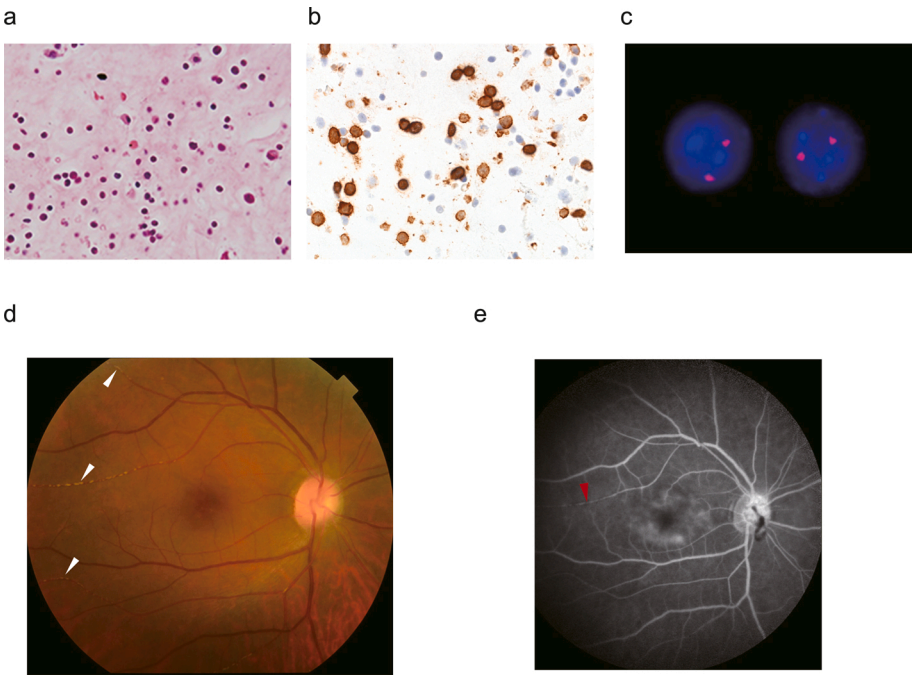

Fig. 2. (**a**) A cellular specimen composed mostly of atypical lymphocytes in vitrectomy cell blocks. (**b**) Representative images of immunohistochemistry of $CD8^+$ cells (brown cells) in vitrectomy cell blocks. (**c**) All $CD8^+$ cells were stained with X-chromosome probes (pink) in interphase fluorescence in situ hybridization using X- and Y-chromosome probes in the vitreous specimen. (**d**) Fundus photograph of the right eye showing depositions of grey-white granules localized on the retinal artery (white arrowhead) in the right eye. (**e**) Fluorescence angiography showing hyperfluorescence around the macula, hypofluorescence in the retinal artery (red arrowhead), and no leakage from the vessels. (For interpretation of the references to colour in this figure legend, the reader is referred to the Web version of this article.)

infect various types of cells including $CD4^+$ and $CD8^+$ T lymphocytes and monocyte/macrophages, the principal target of HTLV-1 virus infection is $CD4^+$ T cells. Therefore, the phenotype of clonal expansion of ATL cells is generally identified as $CD3^+$, $CD4^+$, and $CD8^-$ in majority cases, whereas it is either $CD3^+$, $CD4^+$, and $CD8^+$, $CD3^+$, $CD4^-$, and $CD8^+$, or $CD3^+$, $CD4^-$, and $CD8^-$ in some cases.[16] Clonal expansion of HTLV-1-infected $CD4^+$ T lymphocytes, but not $CD8^+$ lymphocytes, leads to a malignant phenotype and subsequent tumorigenesis.[17] Approximately 5% of HTLV-1-infected individuals develop ATL 30–50 years after the initial infection.[18] ATL recurs owing to the growth of recipient-derived ATL cells after allo-HSCT.[19] Thus, these results suggest that donor-derived HTLV-1-infected $CD8^+$ T lymphocytes were not cancerous in this case because of the short period of transformation to ATL cells, although HTLV-1 transmission can occur from recipient cells to donor cells.[20]

Inflammatory cell infiltration accompanied by ATL cells, which is known as ATL-cell induced uveitis (AIU),[6] was a dominant candidate in this case because ATL had recurred in the skin 6 months prior. Moreover, the incidence of intraocular tumor cell invasion is prevalent in patients with ATL in Japan.[5] Allogeneic HSCT induces a graft-versus-ATL effect, which is a HTLV-1-specific CTL response to combat ATL cells after HSCT, causing improvement in the clinical course of ATL.[12] In this case, the patient achieved CR after HSCT and survived longer than the mean survival time, indicating that allogeneic HSCT successfully induced HTLV-1-specific CTL responses. These results suggest that infiltration of donor-derived $CD8^+$ T lymphocytes was associated with AIU. However, in this case, cytological analysis did not show any signs of ATL cell invasion, indicating that recipient-derived ATL cells had invaded at the onset but were killed by donor-derived $CD8^+$ T cells before vitrectomy.

In patients with HAU, HTLV-1 is potent in infecting intraocular cells, including retinal pigment epithelial (RPE) cells.[21,22] HTLV-1-infected RPE cells impair retinal homeostasis and promote the expression of intercellular adhesion molecule-1 on RPEs to attract HTLV-1.[21] In an analysis of a murine HTLV-1 model, cross-reactivity of HTLV-1 antigen with retinal antigens induced proinflammatory responses in the retina.[23] Therefore, these results suggest that donor-derived $CD8^+$ T lymphocytes accumulate and elicit inflammatory responses similar to those in HAU to eliminate HTLV-1-infected intraocular cells, such as RPE cells, and/or to react retinal antigens in the eye of the recipient, although there is no evidence of persistent HTLV-1 infection in intraocular cells, including RPE cells, in this case. Further studies are necessary to determine whether persistent HTLV-1 infection exists in intraocular cells in patients with ATL.

4. Conclusions

To our knowledge, this is a primary case of panuveitis induced by donor-derived $CD8^+$ T lymphocytes in a patient with aggressive ATL after allo-HSCT. The number of cases with donor-derived inflammatory cell infiltration may increase because allo-HSCT can elicit strong HTLV-1-specific CTL responses, thereby improving the prognosis in some cases of ATL.[24] Vitrectomy is useful for the differential diagnosis of ATL cell invasion, opportunistic infections, and inflammatory cell infiltrates such as HAU. Detection of donor-derived $CD8^+$-T cell infiltration in the eye may be a sign of inflammatory cell responses, including ATL-cell-induced uveitis. Furthermore, donor-derived $CD8^+$ T lymphocytes-induced uveitis is recurrent but well-controlled because of its susceptibility to regional corticosteroid treatment in patients with ATL after allo-HSCT.

Patient consent

Written consent to publish this case has not been obtained. This report does not contain any personal identifying information.

Authorship

All authors declare that they meet the current ICMJE criteria for authorship.

Declaration of competing interest

Atsunobu Takeda received grants from Alcon, AMO Japan, Novartis, and Santen Pharmaceutical; and lecture fees from Novartis, AMO Japan, and NIDEK CO., Ltd. Koh-Hei Sonoda received grants from Alcon, Novartis, and AMO Japan; and lecture fees from Santen Pharmaceutical, Alcon, AMO Japan, Bayer, Novartis, Kowa Pharmaceutical, Senju Pharmaceutical, Otsuka Pharmaceutical, and RE Medical; consulting

fees from Kowa, JT, and Abbvie; lecture fees from Novartis, Bayer Pharma, Canon Inc., Santen Pharmaceutical, Kowa, Senju Pharmaceutical, Ono Pharmaceutical, MSD, HOYA, Wakamoto, AMO, Alcon, Otsuka Pharmaceutical, AbbVie Eisai, Nidek, Topcon, Novo Nordisk, Mitsubishi Tanabe Pharma, Sumitomo Dainippon Pharma, and Astellas. The following authors have no financial disclosures related to this work: TS, NY, KK, EH, TS, SH, KY, NK, MH, RT, YW, KT, YO, and KA.

References

1. El Hajj H, Tsukasaki K, Cheminant M, Bazarbachi A, Watanabe T, Hermine O. Novel treatments of adult T cell leukemia lymphoma. *Front Microbiol*. 2020;11:1062.
2. Satake M, Yamada Y, Atogami S, Yamaguchi K. The incidence of adult T-cell leukemia/lymphoma among human T-lymphotropic virus type 1 carriers in Japan. *Leuk Lymphoma*. 2015;56:1806–1812.
3. Imaizumi Y, Iwanaga M, Nosaka K, et al. Prognosis of patients with adult T-cell leukemia/lymphoma in Japan: a nationwide hospital-based study. *Cancer Sci*. 2020; 111:4567–4580.
4. Cook LB, Phillips AA. How I treat adult T-cell leukemia/lymphoma. *Blood*. 2021; 137:459–470.
5. Kamoi K, Okayama A, Izumo S, et al. Adult T-cell leukemia/lymphoma-related ocular manifestations: analysis of the first large-scale nationwide survey. *Front Microbiol*. 2018;9:3240.
6. Hirano M, Ohno N, Tanosaki R, et al. Adult T-cell leukemia cell-induced uveitis: rapid increase in adult T-cell leukemia cells disrupts the blood-ocular barrier. *Int J Hematol*. 2017;106:842–846.
7. Shibata K, Shimamoto Y, Nishimura T, Okinami S, Yamada H, Miyahara M. Ocular manifestations in adult T-cell leukemia/lymphoma. *Ann Hematol*. 1997;74:163–168.
8. Brites C, Grassi MF, Quaresma JAS, Ishak R, Vallinoto ACR. Pathogenesis of HTLV-1 infection and progression biomarkers: an overview. *Braz J Infect Dis*. 2021;25, 101594.
9. Kamoi K, Mochizuki M. HTLV-1 uveitis. *Front Microbiol*. 2012;3:270.
10. Kannagi M, Hasegawa A, Takamori A, Kinpara S, Utsunomiya A. The roles of acquired and innate immunity in human T-cell leukemia virus type 1-mediated diseases. *Front Microbiol*. 2012;3:323.
11. Greten TF, Slansky JE, Kubota R, et al. Direct visualization of antigen-specific T cells: HTLV-1 Tax11-19- specific CD8(+) T cells are activated in peripheral blood and accumulate in cerebrospinal fluid from HAM/TSP patients. *Proc Natl Acad Sci U S A*. 1998;95:7568–7573.
12. Harashima N, Kurihara K, Utsunomiya A, et al. Graft-versus-Tax response in adult T-cell leukemia patients after hematopoietic stem cell transplantation. *Cancer Res*. 2004;64:391–399.
13. Tsukasaki K, Hermine O, Bazarbachi A, et al. Definition, prognostic factors, treatment, and response criteria of adult T-cell leukemia-lymphoma: a proposal from an international consensus meeting. *J Clin Oncol*. 2009;27:453–459.
14. Ohba N, Nakao K, Isashiki Y, et al. Clinical features of HTLV-I associated uveitis determined in multicenter collaborative study. Study Group for HTLV-I Associated Ocular Diseases. *Jpn J Ophthalmol*. 1994;38:168–174.
15. Cook LB, Fuji S, Hermine O, et al. Revised adult T-cell leukemia-lymphoma international consensus meeting report. *J Clin Oncol*. 2019;37:677–687.
16. Kamihira S, Sohda H, Atogami S, et al. Phenotypic diversity and prognosis of adult T-cell leukemia. *Leuk Res*. 1992;16:435–441.
17. Sibon D, Gabet AS, Zandecki M, et al. HTLV-1 propels untransformed CD4 lymphocytes into the cell cycle while protecting CD8 cells from death. *J Clin Invest*. 2006;116:974–983.
18. Bangham CR, Ratner L. How does HTLV-1 cause adult T-cell leukaemia/lymphoma (ATL)? *Curr Opin Virol*. 2015;14:93–100.
19. Kawano N, Yoshida S, Kawano S, et al. The clinical impact of human T-lymphotrophic virus type 1 (HTLV-1) infection on the development of adult T-cell leukemia-lymphoma (ATL) or HTLV-1-associated myelopathy (HAM)/atypical HAM after allogeneic hematopoietic stem cell transplantation (allo-HSCT) and renal transplantation. *J Clin Exp Hematop*. 2018;58:107–121.
20. Kitamura N, Nakanishi T, Yoshida Y, Higashi T, Tsukada J. HTLV-I-associated posttransplant lymphoproliferative disorder following virus transmission from recipient to donor cells. *Blood*. 2017;130:84–86.
21. Liu B, Li Z, Mahesh SP, Kurup SK, Giam CZ, Nussenblatt RB. HTLV-1 infection of human retinal pigment epithelial cells and inhibition of viral infection by an antibody to ICAM-1. *Invest Ophthalmol Vis Sci*. 2006;47:1510–1515.
22. Uchida M, Kamoi K, Ando N, Wei C, Karube H, Ohno-Matsui K. Safety of infliximab for the eye under human T-cell leukemia virus type 1 infectious conditions in vitro. *Front Microbiol*. 2019;10:2148.
23. Fukushima A, Ueno H, Fujimoto S. Antigenic cross-reactivity between human T lymphotropic virus type I (HTLV-I) and retinal antigens recognized by T cells. *Clin Exp Immunol*. 1994;95:459–464.
24. Shiratori S, Yasumoto A, Tanaka J, et al. A retrospective analysis of allogeneic hematopoietic stem cell transplantation for adult T cell leukemia/lymphoma (ATL): clinical impact of graft-versus-leukemia/lymphoma effect. *Biol Blood Marrow Transplant*. 2008;14:817–823.